

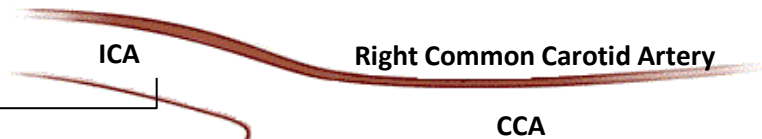


## Carotid Duplex Report

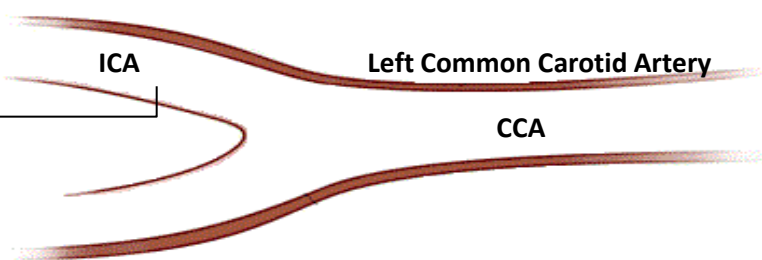
**Patient Name:** SAUNDERS, BETH  
**DOB:** 5-Jun-56

**Physician:** RASTOGI  
**Exam Date:** 3-Aug-23

<b>Right</b>	<b>ICA</b>	<b>CCA</b>
<b>*PSV:</b>	<b>51</b>	<b>53</b>
<b>*EDV:</b>	<b>17</b>	<b>25</b>
<b>RICA STENOSIS:</b>	<b>&lt; 20%</b>	



<b>Left</b>	<b>ICA</b>	<b>CCA</b>
<b>*PSV:</b>	<b>40</b>	<b>47</b>
<b>*EDV:</b>	<b>34</b>	<b>17</b>
<b>LICA STENOSIS:</b>	<b>&lt; 20%</b>	



**Left Vertebral Artery**  
**Velocity:** 39  
**Direction:** Antegrade

**Right Vertebral Artery**  
**Velocity:** 40  
**Direction:** Antegrade

**Vertebral Artery**



COMMENT: Dynamic ultrasound scanning of the neck was performed with carotid duplex (Doppler & B-Mode ultrasound) arterial analysis including color flow and spectral analysis; Impression: Normal bilateral carotid duplex ultrasound exam.

Physicians Signature: \_\_\_\_\_



